

# Crusted (Norwegian) Scabies in a Malnourished Geriatric Patient with Dementia

Zehra Çağla Karakoç<sup>1</sup> , Ahmet Başel<sup>2</sup> , Yeşim Koçak<sup>3</sup> , Binnur Pınarbaşı Şimşek<sup>4</sup> ,  
Simru Tuğrul<sup>2</sup> , Figen Akın<sup>5</sup> 

<sup>1</sup> Department of Infectious Diseases and Clinical Microbiology, İstinye University School of Medicine, İstanbul, Turkey

<sup>2</sup> Department of Anesthesiology and Reanimation, İstinye University School of Medicine, İstanbul, Turkey

<sup>3</sup> Infection Control Nurse, Liv Hospital-Ulus, İstanbul, Turkey

<sup>4</sup> Department of Gastroenterohepatology, İstinye University School of Medicine, İstanbul, Turkey

<sup>5</sup> Dermatology, Liv Hospital-Ulus, İstanbul, Turkey

## ABSTRACT

Norwegian scabies, which is a highly contagious variant of scabies, is a common parasitic infestation in elderly persons living in care homes. Clinical symptoms may be different in this patient group (slow onset and insidious progression, often without intense itching) with the addition of comorbid conditions, such as dementia and neurological diseases. Healthcare workers should be aware of this form of scabies, which is more common in elderly and cognitively impaired patients. Early diagnosis can be made easily by a microscopic examination of skin lesions. Isolation precautions are important measures to prevent outbreaks. The treatment includes keratolytic agents besides topical and oral scabicides because of the high mite burden and hyperkeratotic lesions of the crusted scabies. In this study, we reported on a case who had resided in a geriatric care home. The patient was diagnosed with crusted scabies and died in our intensive care unit with pneumonia.

**Keywords:** scabies, elderly, dementia, mites, *Sarcoptes scabiei*

## INTRODUCTION

Crusted scabies, also called Norwegian scabies, was first described in Norway in the middle of the 19th century. It is a highly contagious and rare form of scabies. Patients who are elderly, immunocompromised, malnourished, or have neurologic conditions that prevent them from itching are at greater risk. It is characterized by vesicles and thick crusts over the skin that contain millions of *Sarcoptes scabiei* mites. Although the predominant route of transmission is skin-to-skin contact, crusted scabies can be transmitted indirectly via patients' bedding, clothes, or surroundings, and can cause outbreaks in institutional settings or nursing homes. Here, we report a case of Norwegian scabies in an elderly patient who resided in a nursing home (1-3).

### Corresponding Author:

Zehra Çağla Karakoç

### E-mail:

ckarakoc@gmail.com

**Received:** June 29, 2020

**Accepted:** October 05, 2020

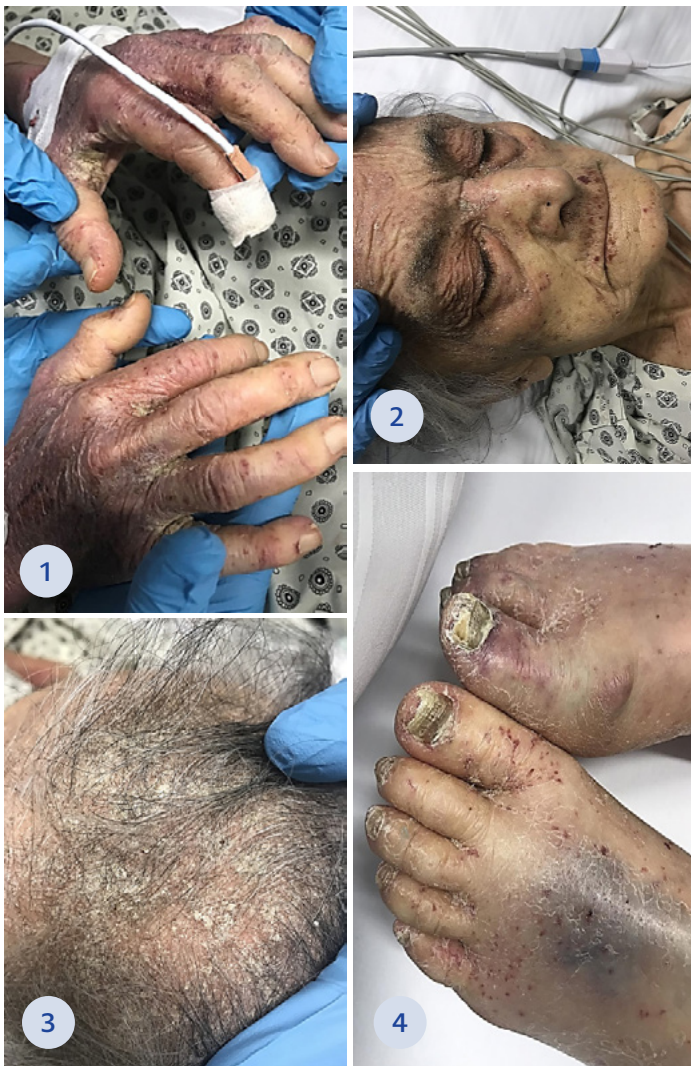**Published:** November 20, 2020

### Suggested citation:

Karakoç ZÇ, Başel A, Koçak Y, Şimşek BP, Tuğrul S, Akın F. Crusted (Norwegian) Scabies in a Malnourished Geriatric Patient with Dementia. Infect Dis Clin Microbiol 2020; 3

**DOI:** 10.36519/idcm.2020.0017





**Figure 1-4.** Erythematous papules and vesicles, hyperkeratotic plaques and papules primarily on the scalp, face, hands and feet.

### CASE PRESENTATION

An 88-year-old female resident of a care home was admitted to our intensive care unit with fever and respiratory distress. The patient had been bed-ridden for two years and had chronic obstructive pulmonary disease and dementia diagnoses. On admission, she was confused, in a generally poor condition and asthenic. Her body temperature was 37.8° C, pulse rate 94 beats/min, blood pressure 90/60 mmHg, respiratory rate 25/min, and SpO<sub>2</sub> 90% at room temperature. Upon physical examination, she was noted to have hyperkeratotic plaques with yellow crusts on the scalp, face, hands, and

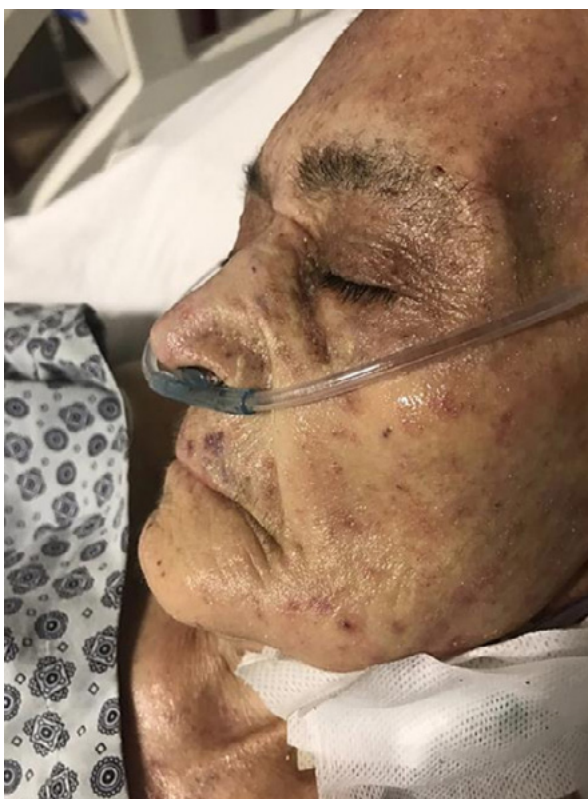feet (Figure 1-4). A respiratory examination revealed crepitation in both lower lungs. Other system examinations were unremarkable.

Laboratory analysis revealed leukocytosis (19600/mm<sup>3</sup>), polymorphonuclear leukocyte (94.7%), anemia (Hb:9 mg/dl, Hct:32.4), thrombocytopenia (60000/mm<sup>3</sup>), hypoalbuminemia (1.8g/dL), hyperchloremia (120.6 mmol/L), hypernatremia (151 mmol/L), azotemia (creatinine: 2.04 mg/dL), elevation of C-reactive protein (246.7mg/L) and procalcitonin (5.85 ng/mL). Viral serologic markers for hepatitis B, hepatitis C, and HIV were negative. A chest X-ray showed consolidation in the middle lobe of the left lung. Blood and urine cultures were collected. Antimicrobial therapy (ceftriaxone and clarithromycin) were empirically started.

A dermatology consultation was performed for the cutaneous findings and keratotic plaques on the scalp, face, hands, and feet. The widespread excoriated scaly eruption, papules, and vesicles on the body were detected. A potassium hydroxide microscopic wet-mount examination of the skin scales showed scabies mites and eggs (Figure 5). Norwegian scabies was diagnosed with clinical and microscopic findings.

Urgent isolation measures (contact precautions) were taken by the hospital infection control team, according to the Centers for Disease Control and Prevention protocol, to avoid nosocomial transmission (4). Intensive care unit personnel were rapidly trained about scabies and infection control measures. Personal protective equipment (gloves, long-sleeved gowns, shoe covers, surgical masks) and hand hygiene compliance of the staff providing care to the patient were ensured. The bedding of the patient was transported in a plastic bag and washed in a separate washing machine at over 60° C. Also, the laundry personnel used personnel protective garments when handling the laundry. The patient's room was cleaned regularly for skin crusts that can contain a large number of mites. Intensive care unit caregivers were advised to bathe every day with sulphur soap.

The dermatologist recommended a pharmacological treatment of the patient with oral (ivermectin

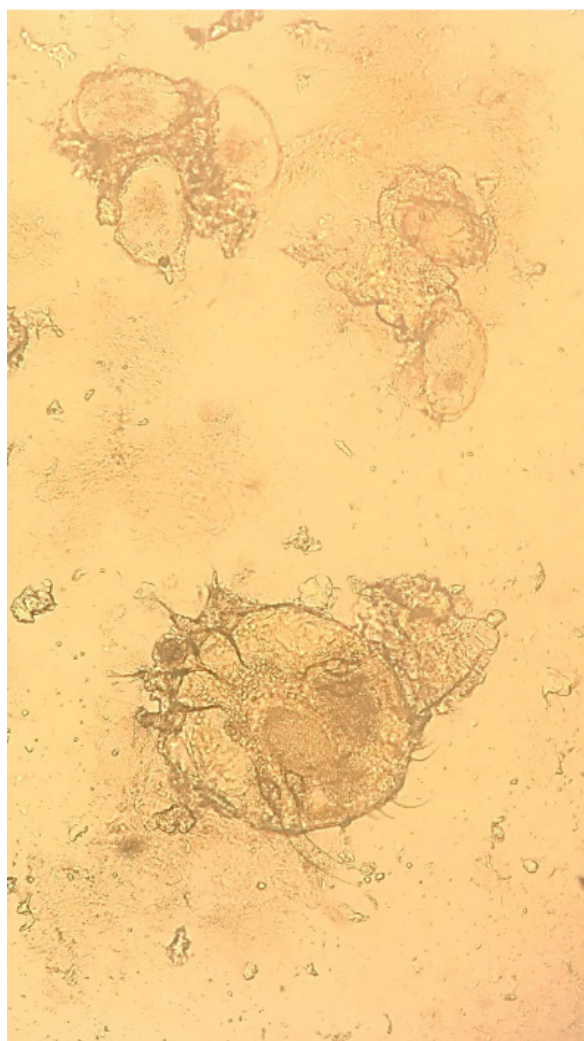


**Figure 5.** Regression of the lesions on the face after treatment.

tab 200 µg/kg PO one dose and repeated after one week) and topical medication (salicylic Vaseline 15% between fingers 2 × 1; scalp rubbing with oil and limestone ointment at night, and washing with sulphur soap in the morning; precipitated sulphur 30 gr + cade oil 20 gr + lanoline 60 gr + Vaseline 90 gr applied on her entire body every night, and washing with sulphur soap every morning for four consecutive days) simultaneously. We observed regression after treatment (Figure 6). However, the patient died of pneumonia on her fifth day of hospitalization due to her advanced age and comorbidities. *Klebsiella pneumoniae* was isolated in the endotracheal aspirate. The Communicable Disease Control Unit was notified that a patient from the nursing home had been diagnosed with Norwegian scabies.

## DISCUSSION

Half of the patients with scabies who live in nursing homes do not exhibit the typical signs and symptoms, as the disease progresses asymptotically. Scabies outbreaks are common in these institutions



**Figure 6.** Scabies mite and eggs under light microscopy (mounted in KOHX400).

because of delayed diagnosis and the demanding effort required to control infection. Norwegian scabies, specifically, has a huge mite burden, is highly contagious, and can cause epidemics in these long-term care facilities (5-7). Factors that predispose an individual to crusted scabies include immunosuppression, neurological diseases, advanced age, malnutrition, and institutionalization (7-9). In our case, advanced age, malnutrition, and dementia were the main risk factors that caused a reduced ability to control the proliferation of the mites.

The diagnosis of scabies is made clinically, but definitive diagnosis is based on a low power microscopic examination of a burrow skin scraping. In

Norwegian scabies, as crusts contain large numbers of mites and eggs, diagnosis can be made easily with excellent specificity and sensitivity. However, in classic scabies, sensitivity is low due to low numbers of mites. Also, an increased number of scrapings, sampling of unscratched lesions and experience of the individual performing the examination are factors that increase sensitivity. Histopathological findings may also confirm the diagnosis (3,10). Among the diseases that should be taken into consideration in the differential diagnosis are psoriasis and atopic dermatitis, especially in elderly patients (2). Although no standardized protocols are available, treatment includes keratolytic agents besides topical and oral scabicides because of the high mite burden and hyperkeratotic lesions of the crusted scabies. Ivermectin is the systemic drug of choice (7).

## CONCLUSION

Considering that the number of people who require care in a nursing home is increasing with the aging world population, infectious diseases, such as scabies, will continue to be among a considerable public health issue in this age group. Norwegian scabies disease is commonly documented in nursing homes, as in our case. Healthcare workers should be aware of this form of scabies, which is highly contagious and seen more common in elderly and cognitively impaired patients. Therefore, early diagnosis, which can be made easily by microscopic examination of skin lesions and isolation precautions, are important measures to prevent outbreaks in both settings.

**Informed Consent:** Written consent was obtained from the patient relatives.

**Peer-review:** Externally peer-reviewed

**Author Contributions:** Concept - ALL; Design - ALL; Supervision - ALL; Materials - Z.Ç.K., Y.K., A.B.; Data Collection and/or Processing - Z.Ç.K., Y.K., F.A.; Analysis and/or Interpretation - ALL; Literature

Review - Z.Ç.K., B.P.S., F.A.; Writer - Z.Ç.K.; Critical Reviews - ALL.

**Conflict of Interest:** The authors have no conflict of interest to declare.

**Financial Disclosure:** The authors declared that this study has received no financial support

## REFERENCES

- Centers for Disease Control and Prevention. Parasites. Epidemiology and risk factors. Crusted (Norwegian) scabies (cited 2020 June 19). Available from: URL: <https://www.cdc.gov/parasites/scabies/epi.html>.
- Raffi J, Suresh R, Butler DC. Review of scabies in the elderly. *Dermatol Ther* (Heidelb) 2019; 9: 623-30.
- James H. Diaz. Scabies. Bennett JE, Dolin R, Blaser MJ, editors. Mandell, Douglas, and Bennett's principles and practice of infectious diseases. 8th ed. Philadelphia, PA: Saunders; 2015. p. 3250-4.
- Centers for Disease Control and Prevention. Parasites. Scabies. Prevention and control (cited 2020 June 19). Available from: URL: <https://www.cdc.gov/parasites/scabies/prevent.html>.
- Hewitt KA, Nalabanda A, Cassell JA. Scabies outbreaks in residential care homes: factors associated with late recognition, burden and impact. A mixed methods study in England. *Epidemiol Infect* 2015; 143: 1542-51.
- Cassell JA, Middleton J, Nalabanda A, Lanza S, Head MG, Bostock J, et al. Scabies outbreaks in ten care homes for elderly people: a prospective study of clinical features, epidemiology, and treatment outcomes. *Lancet Infect Dis* 2018; 18: 894-902.
- Karthikeyan K. Crusted scabies. *Indian J Dermatol Venereol Leprol* 2009; 75: 340-7.
- Lay CJ, Wang CL, Chuang HY, Chen YL, Chen HL, Tsai SJ, et al. Risk factors for delayed diagnosis of scabies in hospitalized patients from long-term care facilities. *J Clin Med Res* 2011; 3: 72-7.
- Roberts LJ, Huffam SE, Walton SF, Currie BJ. Crusted scabies: clinical and immunological findings in seventy-eight patients and a review of the literature. *J Infect* 2005; 50: 375-81.
- Walton SF, Currie BJ. Problems in diagnosing scabies, a global disease in human and animal populations. *Clin Microbiol Rev* 2007; 20: 268-79.